

ARTICLE

Sequence Analysis of TNFRSF13b, Encoding TACI, in a Patient with Very Early Onset Inflammatory Bowel Disease: a Case Report

Jiaying Shen*

The Children's Hospital, Zhejiang University School of Medicine, Hangzhou, Zhejiang, 310052, China

ARTICLE INFO

Article history:

Received: 5th July 2018

Revised: 31st July 2018

Accepted: 18th October 2018

Published Online: 31st October 2018

Keywords:

VEO-IBD

TNFRSF13B

TACI

Treatment

Mutation

ABSTRACT

Very early onset inflammatory bowel disease (VEO-IBD), IBD diagnosed before 6 years of age, frequently presents with increased severity, aggressive progression, and often poor response to conventional treatments. Although the cause of IBD is generally considered to be intestinal immune dysfunction induced by polygenic mutations and environment and other factors, VEO-IBD has a stronger genetic susceptibility specifically the neonatal- or infantile-onset IBD. Herein we report compound heterozygous mutations in the tumor necrosis factor receptor superfamily member 13b (TNFRSF13B) gene in a 3-year-old male that was admitted to our hospital with lasted jaundice, repeated fever and diarrhea in May 2014 at 2-month-old. He was diagnosed with VEO-IBD based on clinical, laboratory and histopathological examination. However, he was unresponsive to the conventional therapy, including the nutritional support therapy, antibiotic and immunosuppressive treatment, and surgical release of neonatal intestinal obstruction. Novel compound heterozygous mutations, c.[365G>A];[452C>T] (p.[R122Q];[P151L]), were discovered in TNFRSF13B, encoding TACI, for this patient.

1. Case Report

We describe the case of a 3-year-old male referred to our hospital (the Children's Hospital Affiliated to Zhejiang University) in May 2014 at 2-month-old. The patient was admitted to the gastroenterology department for lasted jaundice, repeated fever and diarrhea. During the period of hospitalization, he was found hepatosplenomegaly at 3-month-old and perianal abscess together with neoplasm at 2-year-old. He was G1P1 and full-term caesarean delivered with low birth

weight (LBW) of 1.7kg. Mixed feeding after birth, he was added complementary food at the age of one. Physical examination showed poor reaction, severe malnutrition profile (height and weight -3SD), abdominal distention, hepatomegaly (subcostal 3cm and subxyphoid 2cm) and splenomegaly (line 1 was 5cm, line 2 was 6cm, line 3 was -4cm). Besides, several perianal neoplasms and abscess were visible without ulceration or pus. Laboratory data were the following; white blood cell count $4.78 \times 10^9/L$ (normal: $4.0-8.0 \times 10^9/L$), hemoglobin 7.0 g/dL (normal: 12.0-16.0 g/dL), hs-CRP fluctuated between 10-200mg/L

*Corresponding Author:

Jiaying Shen,

The Children's Hospital, Zhejiang University School of Medicine,

No. 3333 Binsheng Road, Hangzhou, Zhejiang, 310052, China;

E-mail: 527162698@qq.com.

(normal: <8mg/L). CMV antibodies of IgM and IgG were both positive. The liver function test prompted significantly increased total bilirubin, mainly direct bilirubin which lasted for 3 months. Alanine aminotransferase (ALT), serum aspartate aminotransferase (AST) and alkaline phosphatase levels were also elevated. Serum immunoglobulin showed only IgM mild decline, while IgG/IgA had no obvious abnormality (serum IgG 6.40g/l (normal: 4.0-5.0g/l), serum IgA 0.39g/l (normal: 0.1-0.4g/l), and serum IgM 0.43g/l (normal: 0.5-1.0g/l)). The activity of coagulation factors II, VII, IX, XI, XII, as well as the level of insulin and growth hormone remarkably decreased. Apart from those, several tests such as tuberculosis, fungi, cerebrospinal fluid and blood culture were negative. Because of lasted jaundice, laparoscopic bile duct exploration, cholangiography and cholangiography were performed which finally proved cholestasis. In the meanwhile, liver biopsy also showed hepatic cholestasis, punctate necrosis with a slight reduction in the interlobular bile duct. Repeated abdominal radiographs showed intestinal inflation and morphological rigidity. In the chest X-ray, the only findings were bronchiectasis in both lungs and osteoporosis. Total digestive tract radiography, abdomen CT and abdomen B ultrasound demonstrated hepatosplenomegaly and mesenteric vascular changes in spiral shape which indicated congenital malrotation of intestine. Plus, perianal B ultrasound showed perianal hypoechoic area of 0.8*0.3cm and cervical lymph node B ultrasound showed bilateral cervical lymph node enlargement. When applied biopsy of enlarged cervical lymph node, it revealed reactive hyperplasia. Then Small intestinal hydro-MRI was performed (Figure 1) and large intestine radiography (Figure 2) where there were signs compatible with inflammatory bowel disease at colonic, rectum, sigmoid colon levels. Colonoscopy showed multiple colorectal ulcers, partly longitudinal ulcers, and cobblestone change of the mucosa in the transverse colon (Figure 3); biopsies were taken at both levels. The anatomical-pathological examination of the samples reported fissure ulcer, focal crypt abscess, and chronic active inflammation of the mucosal epithelium, in which the goblet cells decreased while lamina propria lymphocytes, plasma cells, neutrophils and eosinophils increased (1-26/HP) (Figure 4). During the period of hospitalization, he underwent intestinal resection and colostomy for releasing of neonatal intestinal obstruction. In macroscopic examination (Figure 5), mucosa was hemorrhagic and hyperemic; multiple foci of ulcer and cobblestone change of the mucosa were seen. Genetic analysis revealed heterozygous mutations in TNFRSF13B, encoding TACI (Figure 6). Drugs such as antibiotics, antivirals, antifungals, intermittent intravenous immunoglobulin,

hormone (Prednisone), aminosalicic acid (Mesalazine), immunosuppressant (6-Mercaptopurine, Methotrexate, Thalidomide), biological treatment of anti TNF agents (which was withdrawn after anaphylactic shock occurring for second Ciyingfuli Infliximab therapy) were introduced and applied. The condition could take a favorable turn, but was of short duration. Less than 1-2 weeks at home, he would be admitted to our hospital due to recurrent infection.

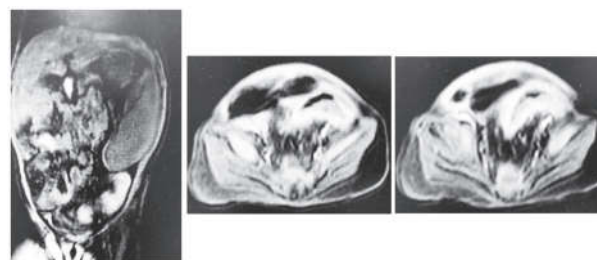


Figure 1

Notes: Small intestinal hydro-MRI image showed splenomegaly, intestinal morphological rigidity at the rectum, sigmoid colon and the right lower abdomen and significant enhancement in T1-weighted sequences after intravenous administration of paramagnetic contrast medium.

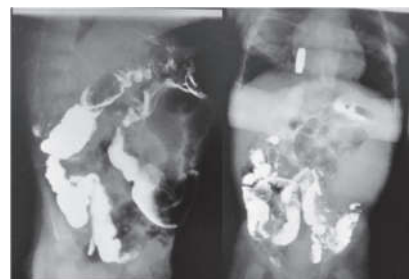

Figure 2

Notes: Large intestine radiography showed stiff morphology and rough wall of the intestinal canal, as well as slightly dilatation of sigmoid intestinal.

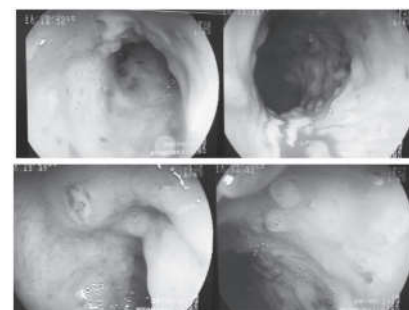


Figure 3

Notes: Colonoscopy image of multiple colorectal ulcers, partly longitudinal ulcers, and cobblestone change of the mucosa in the transverse colon.

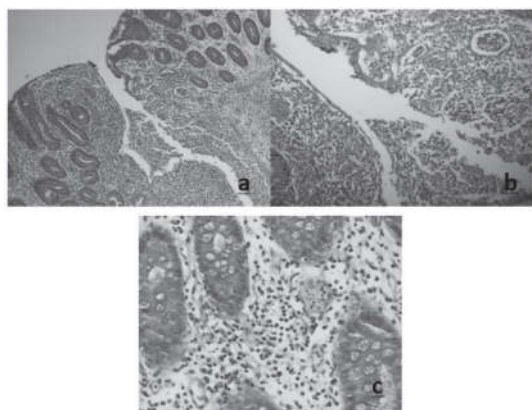


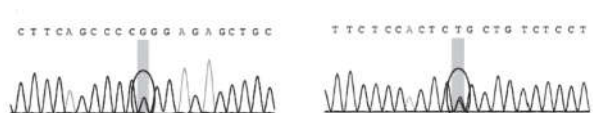
Figure 4

Notes: Pathological images showed fissure ulcer(a), focal crypt abscess(b), and chronic active inflammation of the mucosal epithelium, in which the goblet cells decreased while lamina propria lymphocytes, plasma cells, neutrophils and eosinophils increased(1-26/HP) (c).

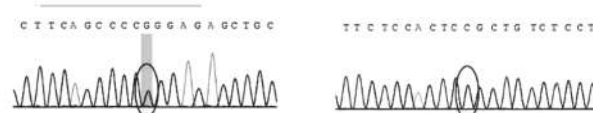


Figure 5

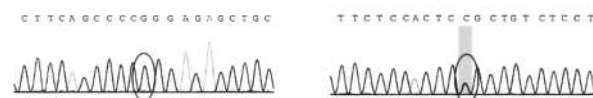
Notes: Macroscopic appearance of colectomy material. Mucosa was hemorrhagic and hyperemic; multiple foci of ulcer and cobblestone change of the mucosa were seen.



Child: chr17:16843819 and chr17:16852132 respectively exist a heterozygous mutation of c.452C>T and c.365G>A



Father: chr17:16843819 exists a heterozygous mutation of c.452C>T, while chr17:16852132 has no mutation



Mother: chr17:16843819 has no mutation, while chr17:16852132 exists a heterozygous mutation of c.365G>A

Figure 6

Notes: Sanger sequencing pictures. Two heterozygous mutations were found in the exon region of TNFRSF13B gene: c.365G > A (guanine > adenine) and c.452C > T (cytosine > thymine). It finally resulted in amino acid change: p.R122Q (arginine > glutamine) and p.P151L (proline > leucine). The double heterozygous mutations of TNFRSF13B gene, which are known as compound heterozygous mutations, were respectively from the parents and were consistent with autosomal recessive inheritance.

2. Discussion

Inflammatory bowel disease (IBD), including ulcerative colitis (UC), Crohn's disease (CD) and unclassified IBD (IBDU), is a group of chronic recurrent disease with complex pathogenesis and multiple factors related. Although the exact etiology of IBD is not yet completely known, recent studies have indicated that personal genetic susceptibility, environment, intestinal microbiota, and immune system are all involved.^[1] With the technological progress in genetic testing and DNA sequencing, the most recent and largest genetic association study, which employed genome-wide association data for over 75,000 adolescent and adult-onset IBD patients and controls, identified 163 genes for IBD.^[2] More recently, a trans-ethnic analysis including over 20,000 individuals of European and non-European ancestry identified an additional 38 new IBD genes.^[3] While very early onset inflammatory bowel disease (VEO-IBD), IBD diagnosed before 6 years of age,^[4] frequently present with increased severity, aggressive progression, and often poor response to conventional treatments, is supported to have a stronger genetic susceptibility specifically the neonatal- or infantile-onset IBD.^[5] Especially when some related genes mutations are found in recent years, such as IL-10RA/B,^[6] IL-10,^[7] XIAP,^[8] ADAMI7,^[9] etc., it makes some VEO-IBD become single gene diseases, many of which are classified as primary immunodeficiency disease(PIDs).

When it comes to this case, the child was then diagnosed as VEO-IBD based on clinical history, physical examination, endoscopic appearance, histologic findings, and radiologic studies, according to Porto criteria.^[10] However, he was unresponsive to the conventional therapy, including the nutritional support therapy, antibiotic and immunosuppressive treatment, or surgical release of neonatal intestinal obstruction. Not until he was 2 years old, compound heterozygous mutations, c.[365G>A];[452C>T] (p.[R122Q];[P151L]), were discovered in the exon region of TNFRSF13B gene, encoding TACI, using whole exome sequencing (WES) analysis of DNA collected from the patient and his parents. And the two heterozygous mutations were respectively from the parents and were consistent with autosomal recessive inheritance.

TACI molecules, containing 293 amino acids, are mainly expressed in B cells or activated T cells. The cod-

ing gene TNFRSF13B is located on 17p and contains 5 exons. Gene mutations can be distributed in all regions of TAC1. The function of TAC1 molecules are complex and diverse, including promoting isotype switching of mucosal IgA, playing an important role in the negative regulation of B cell activation and amplification, effectively participating in T cell dependent type two immune response molecules.^[11-13] When the encoding gene mutation of TAC1 molecules arise, it will lead to T cells, B cells, antigen-presenting cells and the innate immune receptor deficiency.^[14] There is an extremely convincing that mutations within the TAC1 gene resulting in amino acid substitutions are correlated with common variable immunodeficiency (CVID) and IgA deficient (IgAD) because extensive sequencing in healthy control subjects has failed to show the mutation.^[16,17] In recently, TAC1 has been reported in about 8-10% of CVID patients and selective IgAD but sometimes found in healthy subjects who are not hypogammaglobulinemic.^[17]

According to the diagnostic criteria for CVID published by the European Society for the prevention of immunodeficiency (ESID) and the national immunodeficiency group (PAGID),^[18] CVID shall meet the following requirements: (1) The IgG level is lower than 5 g /L or 2.5 percentage points lower than peers. IgA is usually lower than normal level, while IgM can be normal or reduced; (2) There is no other definite cause of immunodeficiency; (3) Older than 4 years old. While selective IgAD is defined as a primary immunodeficiency characterized by an undetectable level of immunoglobulin A (IgA) in the blood and secretions but no other immunoglobulin deficiencies. In this case, the repeated blood immunoglobulin showed only IgM mild decline, while IgG/IgA had no obvious abnormality. That is, he can't be diagnosed neither as CVID nor selective IgAD at present. But it will still be interesting to follow this patient for the possible evolution of immunodeficiency because most patients with CVID do not present until adulthood.^[19] Maybe, it is because TNFRSF13B defects alone do not cause CVID (or IgA deficient) and such an extremely heterogeneous immunodeficiency might be more likely related to additional, still unknown environmental and genetic factors as previous reports suggested.^[15] Or maybe, these novel compound heterozygous mutations of TNFRSF13B, do not present as CVID (or IgA deficient), can lead to gut inflammation in some elusive way.

3. Conclusion

The key interest point in this report is that novel compound heterozygous mutations were discovered in TN-

FRSF13B, encoding TAC1, for this patient with VEO-IBD. The relationship between the TNFRSF13B mutation and VEO-IBD is unclear, with further identification and follow-up of patients with such mutations needed to demonstrate the relationship between this biologic abnormality and its clinical manifestations. In terms of treatment, hematopoietic stem cell transplantation should be the best radical treatment for IBD with gene mutation, especially for severe and poorly controlled IBD patients. The potential mechanism is to repair the damaged intestinal mucosal barrier through differentiation and proliferation of intestinal stem cells. In principle, if TNFRSF13B deficiency is identified as a cause of primary immunodeficiency and early-onset IBD, it might be amenable to allogeneic hematopoietic stem cell transplantation to correct for the disease.

References

- [1] Loddo I, Romano C. Inflammatory Bowel Disease: Genetics, Epigenetics, and Pathogenesis[J]. *Frontiers in immunology*, 2015, 6:551.
- [2] McGovern D, Kugathasan S, Cho JH. Genetics of inflammatory bowel diseases[J]. *Gastroenterology*, 2015, 149(5):1163-76.
- [3] Liu JZ, Van Sommeren S, Huang H, et al. Association analyses identify 38 susceptibility loci for inflammatory bowel disease and highlight shared genetic risk across populations[J]. *Nat Genet*, 2015, 47(9):979-86.
- [4] Muise AM, Snapper SB, Kugathasan S. The age of gene discovery in very early onset inflammatory bowel disease[J]. *Gastroenterology*, 2012, 143:285-8.
- [5] Snapper SB. Very-Early-Onset Inflammatory Bowel Disease[J]. *Gastroenterol Hepatol (N Y)*, 2015, 11(8):554-556.
- [6] Glocker EO, Kotlarz D, Boztug K, et al. Inflammatory bowel disease and mutations affecting the interleukin-10 receptor[J]. *N Engl J Med*, 2009, 361(21): 2033-2045.
- [7] Glocker EO, Frede N, Perro M, et al. Infant colitis-it's in the genes[J]. *Lancet*, 2010, 376(9748):1272.
- [8] Worthey EA, Mayer AN, Syverson GD, et al. Making a definitive diagnosis; successful clinical application of whole exome sequencing in a child with intractable inflammatory bowel disease[J]. *Genet Med*, 2011, 13(3):255-262.
- [9] Blyden DC, Biancheri P, Di WL, et al. Inflammatory skin and bowel disease linked to Adam17 deletion [J]. *N Engl J Med*, 2011, 365(16):1502-1508.
- [10] Bousvaros A, Antonioli DA, Colletti RB, et al. Differentiating ulcerative colitis from Crohn's disease in children and young adults: report of a working group of the North

- American Society for Pediatric Gastroenterology, Hepatology, and Nutrition and the Crohn's and Colitis Foundation of America[J]. *J Pediatr Gastroenterol Nutr*, 200, 44:653-674.
- [11] Castigli E, Wilson SA, Scott S, et al. TACI and BAFF-R mediate isotype switching in B cells[J]. *J Exp Med*, 2005, 201:35-9.
- [12] Sakurai D, Kanno Y, Hase H, et al. TACI attenuates antibody production costimulated by BAFF-R and CD40[J]. *Eur J Immunol*, 2007, 37:110-8.
- [13] Litinskiy MB, Nardelli B, Hilbert DM, et al. DCs induce CD40-independent immunoglobulin class switching through BLYS and APRIL[J]. *Nat Immunol*, 2002, 3: 822-9.
- [14] Jinqiu Jiang, Maozhi Tang. Research progress of common variable immunodeficiency[J]. *Journal of Pediatric Pharmacy*, 2015, 21:7.
- [15] Sazzini M, Zuntini R, Farjadian S. An evolutionary approach to the medical implications of the tumor necrosis factor receptor superfamily member 13B (TNFRSF13B) gene[J]. *Genes and immunity* 2009, 10(6):566-78.
- [16] Castigli E, Wilson SA, Gariby L, et al. TACI is mutant in common variable immunodeficiency and IgA deficiency[J]. *Nat Genet* 2005, 37:829-34.
- [17] Salzer U, Chapel HM, Webster ADB, et al. Mutations in TNFRSF13B encoding TACI are associated with common variable immunodeficiency in humans[J]. *Nat Genet* 2005, 37:820-8.
- [18] Berglund LJ, Jones GJ, Murali R, et al. TACI mutation with invasive polyclonal CD81 T-cell lymphoproliferation in a patient with common variable immunodeficiency[J]. *J Allergy Clin Immunol*, 2006, 117(4):870-877.
- [19] Gu Yan, Ran Zhihua. Research progress of bone marrow stem cells in the treatment of inflammatory bowel disease[J]. *Journal of Gastroenterology and Hepatology*, 2009, 18(10):889-892.