

Hemichorea Associated with Non-ketotic Hyperglycemia: A Case Report and Review of the Literature

Qin Xu Qijun Dai*

Hai'an Hospital of traditional Chinese Medicine, Nantong, Jiangsu, 226600, China

ARTICLE INFO

Article history

Received: 7 September 2021

Revised: 14 September 2021

Accepted: 24 January 2022

Published Online: 31 January 2022

Keywords:

Chorea

Diabetes mellitus

Nonketotic hyperglycinemia

ABSTRACT

Hemichorea associated with non-ketotic hyperglycemia (HC-NH) is a rare disease. The purpose of this case report is to introduce a patient with HC-NH and provide a schedule of examination and follow-up treatment. We also reviewed the current understanding of pathophysiology and treatment and how to apply it to our patients. The case involved a 37-year-old Asian diabetic man who had a 9-day history of losing movement in left limbs and face. His initial blood glucose level was 10.13 mmol/L. HbA1c was 13.6%. Before admission, head CT scan showed suspicious small pieces of left brainstem with slightly high-density shadow and right putamen nucleus with high-density shadow. On the day of admission, head MRI showed punctate T1WI low signal shadow, T2WI high and low mixed signal shadow, T1WI high signal shadow and T2WI low signal shadow of right putamen nucleus. The case findings were consistent with his displayed motor pattern and with the HC-NH diagnosis. Gradual control of the blood glucose levels alleviates his choreiform symptoms. The endocrinology follow-up 6 months after discharge found that his symptoms did not recur after the outpatient's medication compliance was improved. HC-NH is a rare manifestation of poor diabetes control, but it should also be noticed by clinicians. Early recognition and gradual treatment of elevated blood glucose levels seem to completely alleviate choreiform symptoms.

1. Introduction

Chorea is brief, quasi-purposeful, irregular muscle contractions, not repetitive or rhythmic, but flows from one muscle to the next and athetosis is slow, writhing,

continuous movements of distal extremities (chiefly the fingers). Metabolic causes have been documented earlier, not worthy of that being Diabetes. Choreoathetosis has been reported earlier in elderly women. We now report a

**Corresponding Author:*

Qijun Dai,

Hai'an Hospital of traditional Chinese Medicine, Nantong, Jiangsu, 226600, China

Email: 2126828166@qq.com

case of hemichoreoathetosis in an Asian male diabetic.

2. Case Presentation

A 37-year-old Asian male presented to our hospital on 29 May 2017 with a 9-day history of acute-onset choreoathetoid movements affected his left limbs and facial muscles. As explained by the patient, the movements were persistent, aggravated with mental strain, and disappeared during sleep. It prevented him from performing his normal daily activities. His medical history included hypertension and weakness in the right limbs from a brainstem hemorrhage which occurred approximately six months prior to the current presentation. He had been diagnosed with diabetes mellitus half a year ago, but was not on any treatment. There was no other relevant past history and family history. The patient had prescriptions for Nifedipine, Irbesartan and Arotinolol. He was not taking any anti-psychotic or anti-seizure medications.

On physical examination, he was revealed to be conscious, had slurring of speech and had repetitive shrugs and rapid swing of his left limbs with no limb weakness, nystagmus or other cerebellar signs. Due to which, the heel-knee-tibia test and finger-nose test could not be performed accurately on his left side. The rest of the nervous system examination was normal.

Common causes of chorea in adult (Sydenham chorea, chronic progressive chorea, acanthocytosis, neoplastic disorders, ischemic or hemorrhagic stroke, and drug toxicity) were considered and were ruled out by appropriate investigations. On admission, his vital signs were as follows: height, 174 cm; weight, 74 kg; blood pressure, 138/92 mmHg; pulse rate, 72 beats/min;

and body temperature, 36.6 °C. No abnormal chest or abdominal findings or edema in his lower extremities were identified on a physical examination. On a laboratory examination, his blood urea nitrogen, and creatinine levels were all elevated. Laboratory examinations on admission showed poorly controlled diabetes mellitus. His fasting blood glucose and hemoglobin levels were 10.13 mmol/L (normal range:3.9-6.1) and 13.6% respectively, urine glucose (++++), and urine ketone (-)(see Table). Renal function tests revealed renal insufficiency. Full blood count, liver function tests, inflammatory markers, thyroid function tests, myocardial enzymogram, blood coagulation, immune index, homocysteine, urine protein electrophoresis, anti-neutrophilic cytoplasmic antibodies and electrocardiogram were normal. A cranial CT scan (29 May 2017) revealed a hyperdense area in the right putamen but no evidence of any acute intracranial pathology (see Figure 1). Brain MRI on day 1 showed high signal intensity on T1-weighted images and low signal intensity on T2-weighted in the same region in addition to the old hemorrhagic sequel lesion. This finding is classic for hyperglycemia-induced hemichorea syndrome.

Based on the above results, the hemichorea induced by the diabetic nonketotic hyperosmolar state was diagnosed. He was started on insulin and good glycemic control was achieved on day 4. The clinical improvement of his condition was correlated to better hyperglycemic control. A week later, the abnormal movements disappeared completely. The patient refused to have a follow-up brain MRI. During his 6 months of follow-up, the patient's blood sugar level was 10 mmol/L and chorea did not recur.

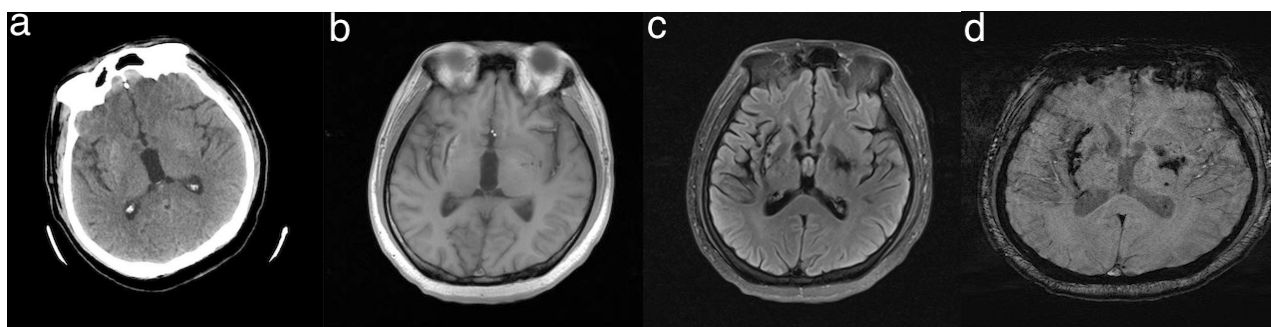


Figure 1. a: Cranial CT shows slight hyperdensity of the right putamen; b: MRI T1-weighted image shows remarkable hyperintensity of the right putamen; c: MRI T2-weighted image shows heterogeneous hyperintensity of the right putamen; d: SWI shows slight hyperintensity of the lesion

Table 1. Laboratory Findings on Admission

Hematology and biochemistry			
WBC	6.46×10 ⁹ /L	BUN	15.37 mmol/L
RBC	4.1×10 ⁹ /L	Cr	273.7µmol/L
Hb	125g/L	Na	140.0 mmol/L
Plt	155×10 ⁹ /L	K	4.5 mmol/L
Tp	61.6 g/L	CL	110 mmol/L
T-Bil	16.7 µmol/L	CK	289 U/L
AST	30.7 U/L	Amy	98 IU/L
ALT	28.3 U/L	NT-pro BNP	187 pg/mL
LDH	235 U/L	Glu	10.13 mmol/L
ALP	81.9 U/L	HbA1c	13.6 %
γ-GTP	52.1 U/L	eGFR	46 mL/min/1.732
ChE	5.8 U/L	D-dimer	1.3 µg/mL

Urinalysis: pH 5.5 Glucose (++++), Protein (-), Occult blood (-), Acetone body (-)

3. Discussion

Hemichorea associated with non-ketotic hyperglycemia (HC-NH) is a rare movement disorder which was first described in 1960 [1]. It is observed in type 2 diabetes and is very rare in patients with type 1 diabetes and diabetic ketoacidosis (DKA). It occurs predominantly in elderly diabetics with unsatisfactory blood glucose control, and women more often than men [2], which could be related to an underlying genetic predisposition [3]. In a meta-analysis of 53 patients [4], mean age was reported as 71 years, while male to female ratio was 1:1.8. A systematic review included 286 patients showed that women and non-ketotic hyperglycemia (NKH) patients were the most frequently affected (63% and 92%, respectively) [5]. Chorea is a relatively uncommon neurological manifestation of diabetes mellitus. Chang CV et al. [6]. Reported 3 cases of new-onset chorea-ballism induced by NKH, highlighting that chorea may be the first manifestation of undiagnosed decompensated diabetes mellitus.

Most patients with chorea associated with NKH have acute or subacute limb involuntary movement (more common on one side), and sometimes involuntary movements of facial muscle, chin, and tongue, accompanied by severe increase in blood glucose and negative ketones in urine. The typical manifestation of NKH chorea is triad: non-ketotic hyperglycemia, hemichorea, and basal ganglia shows high signal in MRI T1 scan or high density in CT scan [7]. In examining this patient, we regarded this as a case of HC-NH due to the unilateral choreoathetotic movement, hyperglycemia on presentation with poor glycemic control, and absent urine ketones, contralateral T1 hyperintensity in the putamen with no restriction on the ADC map, and the absence of

other metabolic derangements.

In general, diabetic lateral chorea caused lesions in the striatum [8]. The development of putamen lesions is unchanged, and there are similar lesions observed in globus pallidus and caudate nucleus. Neurodegenerative diseases that cause basal ganglia injury include Huntington's disease, spinocerebellar degeneration, such as dentatorubral pallidoluysian atrophy, and Creutzfeldt-Jakob disease, which involves elevated ubiquitin levels. These two neurological diseases are progressive in nature, and the treatment has not been determined. These diseases were also excluded because the patient's symptoms improved. Globus pallidus lesions can also be caused by carbon monoxide poisoning; in this case, the lesion shows low signal intensity on T1-weighted images. Other diseases particularly associated with diabetes include mitochondrial diseases, Stiff-person syndrome caused by decreased GABA activity, and myoclonus caused by muscular atrophy of diabetes. The 3243 point mutation in mitochondrial DNA nucleotide sequence is associated with family history of diabetes, and is also observed in mitochondrial encephalomyopathy, lactic acidosis and stroke like episodes (MELAS). It is reported that there is ataxia in MELAS with diabetes mellitus. MELAS showed cerebral infarction like lesions in the occipital region. Stiff-person syndrome is characterized by epileptic muscle spasm in the muscles of the trunk and proximal limbs, which spreads to the whole body within a few months. In our patients, involuntary movement was only present in the left upper and lower limbs; Therefore, Stiff-person syndrome was also excluded.

There are characteristic radiographic manifestations under normal circumstances: the contralateral striatum in MRI T1-weighted show high signal changes and equal

or low signal in MRI T2-weighted, mostly high-density changes in head CT^[9]. The radiological abnormalities are completely reversible^[10]. Despite characteristic imaging findings and clinical manifestations, the underlying mechanism is still unclear. Positron emission tomography (PET) studies were performed in 3 patients at 3 weeks, 5 weeks, and 7 months after clinical onset, showed the markedly reduced rates of cerebral glucose metabolism in the corresponding lesions on MRI T1-weighted^[11]. Additionally, proton MR spectroscopy (MRS) was performed and revealed a decreased N-acetylaspartate/creatine and N-acetylaspartate/choline ratio, indicating neuronal damage of the contralateral putamen^[12]. Findings of the patients' brain have produced an argue about the pathology. In our patient, we can find the contralateral T1 hyperintensity in the putamen. The putamen showed multiple foci of recent infarcts associated with interneuronal response and reactive astrocyte. This suggests a reaction to microinfarction. But histologic examination of the cerebral tissue was obtained some time. There was no blocked vessels. Therefore, histological studies related to brain MRI results are still inconclusive. This requires further research through pathological studies including a large number of patients.

In addition, as mentioned above, few patients have a negative performance on MRI or CT scan. Most patients with this condition have a good prognosis. Controlling blood glucose is the most important treatment. With the decline of blood glucose level, some patients' involuntary movements can be alleviated. To date, only a few negative imaging cases have been reported by other researchers^[13]. According to the current reported cases, we believe that the syndrome can be divided into 2 types: diabetes, ketone negative, hyperglycemia, unilateral or bilateral chorea, while typical imaging changes in head MRI or CT scan are the most common type, and diabetes, hyperglycemia, ketone negative, unilateral or bilateral chorea and negative imaging changes are relatively rare types. We wish to emphasize that NKH chorea with normal imaging can represent a subtype, although this subtype is not common.

At present, the specific mechanism of NKH chorea is not clear. The possible mechanism is that when hyperglycemia occurs, the metabolism of brain cells gradually changes to anaerobic metabolism due to the decrease of local cerebral blood flow and the failure of glucose metabolism. Then γ -aminobutyric acid (GABA) has become the main energy source of brain cells. Acetoacetic acid from ketosis patients can be used to synthesize GABA. GABA in patients with non-ketotic hyperglycemia is rapidly depleted due to lack of acetoacetic acid, so the normal activities of basal ganglia

are impaired^[14]. Scine patients with NKH are prone to chorea.

The pathophysiology of chorea remains to be fully elucidated, but it is believed that it involves the destruction of the balance of neural network activities between the motor cortex and the basal ganglia, including metabolic disorders or structural damage in the subcortical nucleus, caudate nucleus, subthalamic nucleus and thalamus. Potential pathogenetic mechanisms include relative dopaminergic hypersensitivity, impaired synthesis of acetylcholine or gamma-aminobutyric acid, or an undefined effect of hyperosmolarity, perhaps unmasking a previously subclinical lesion of the basal ganglia. In previous studies, typical sites of hemichorea included subthalamic, striatum and basal ganglia^[15]. Functional imaging revealed neuronal loss and dysfunction in many chorea syndromes, as well as changes in metabolism and presymptomatic dopaminergic dysfunction^[16].

Because there are many causes of chorea, the treatment is very challenging. Doctors should collect comprehensive medical history, including medication history of potential pathogens and recent history of streptococcal infection, and examine the nervous and mental systems of patients with symptoms^[17]. Neuroimaging, gene detection and laboratory examinations can confirm the suspected diagnosis of chorea. Mild chorea may not need treatment^[18]. Primary chorea can be treated with dopaminergic antagonists, including antipsychotics; However, side effects including Parkinson's disease and delayed syndrome^[17]. Dopamine depletors that inhibit presynaptic dopamine release and block postsynaptic dopamine receptors are effective, especially in combination with dopamine antagonists^[17]. In the treatment of secondary chorea, the main etiology should be solved. In diabetic chorea, blood glucose control should be optimized. If chorea is caused by drugs or toxicity, the pathogen should be withdrawn. Drugs for the treatment of primary chorea can be used to treat the symptoms of secondary chorea^[17]. Surgical treatments such as pallidotomy and deep brain stimulation may also be an option^[18].

However, not all HC-NH patients can prove this theory through extensive investigation, because of the cost of investigation, such as MRI. In this case, the most likely diagnosis can be obtained using clinical sensitivity and appropriate diagnostic methods. For this patient, combined with clinical history and investigation, other common causes of hemiplegia were excluded. A brain CT scan was performed to rule out other potential risk causes, such as stroke. MRI is undoubtedly the best diagnostic method; however, in some cases, this is not allowed due to accessibility and cost. Nevertheless, it should not be

a limiting factor for primary care doctors to make this diagnosis. Other clinical aspects of medical history and clinical findings can also be used to help diagnose. Due to the elusive nature of this report, clinicians can easily miss it. Therefore, clinicians must be vigilant and keep in mind that such abnormal exercise may occur in patients with poor long-term blood glucose level control, especially in the elderly in Asia. Patients need to be hospitalized for blood glucose normalization, and other potential causes must be excluded. Usually, once the blood glucose level drops to the normal range, abnormal exercise disappears or decreases significantly. However, complete remission varies within days, weeks and months after blood glucose normalization. In some cases, abnormal exercise may last more than a year.

Although this Hemichorea secondary to hyperglycemia is benign and usually has a good prognosis, it has a great impact on patients and their families. Because of this abnormal movement, patients feel disabled and painful, because most of their basic activities take longer to complete, and they need the help of other family members. This has also brought heavy losses to the families. In these cases, it is important to recognize the underlying causes, because correcting potential hyperglycemia usually can quickly alleviate the symptoms. Therefore, clinicians should be resourceful in dealing with patients' biological, psychological and social problems. This case demonstrates that uncontrolled diabetes can be seen as a rare disorder of movement. Being unfamiliar with these situations may lead the attending physician to attribute them to psychological or mental disorders. For all primary care doctors dealing with this common medical problem, a high degree of doubt is necessary.

References

- [1] Bedwell, S.F., 1960. Some observations on hemiballismus. *Neurology*. 10, 619-22.
- [2] Postuma, R.B., Lang, A.E., 2003. Hemiballism: revisiting a classic disorder. *Lancet Neurol*. 2(11), 661-668.
- [3] Kranick, S.M., Price, R.S., Prasad, S., et al., 2008. Clinical reasoning: a 52-year-old woman with subacute hemichorea. *Neurology*. 71(20), e59-62.
- [4] Oh, S.H., Lee, K.Y., Im, J.H., et al., 2002. Chorea associated with non-ketotic hyperglycemia and hyperintensity basal ganglia lesion on T1-weighted brain MRI study: a meta-analysis of 53 cases including four present cases. *J Neurol Sci*. 200(1-2), 57-62.
- [5] Gomez-Ochoa, S.A., Espin-Chico, B.B., Pini-la-Monsalve, G.D., et al., 2018. Clinical and neuroimaging spectrum of hyperglycemia-associated chorea-ballism: systematic review and exploratory analysis of case reports. *Funct Neurol*. 33(4), 175-187.
- [6] Chang, C.V., Felicio, A.C., Godeiro Cde, O., Jr., et al., 2007. Chorea-ballism as a manifestation of decompensated type 2 diabetes mellitus. *Am J Med Sci*. 333(3), 175-177.
- [7] Bizet, J., Cooper, C.J., Quansah, R., et al., 2014. Chorea, Hyperglycemia, Basal Ganglia Syndrome (C-H-BG) in an uncontrolled diabetic patient with normal glucose levels on presentation. *Am J Case Rep*. 15, 143-146.
- [8] Nakajima, N., Ueda, M., Nagayama, H., et al., 2014. Putaminal changes before the onset of clinical symptoms in diabetic hemichorea-hemiballism. *Intern Med*. 53(5), 489-491.
- [9] Zaitout, Z., 2012. CT and MRI findings in the basal ganglia in non-ketotic hyperglycaemia associated hemichorea and hemi-ballismus (HC-HB). *Neuroradiology*. 54(10), 1119-1120.
- [10] Lin, J.J., Lin, G.Y., Shih, C., et al., 2001. Presentation of striatal hyperintensity on T1-weighted MRI in patients with hemiballism-hemichorea caused by non-ketotic hyperglycemia: report of seven new cases and a review of literature. *J Neurol*. 248(9), 750-5.
- [11] Hsu, J.L., Wang, H.C., Hsu, W.C., 2004. Hyperglycemia-induced unilateral basal ganglion lesions with and without hemichorea. A PET study. *J Neurol*. 251(12), 1486-1490.
- [12] Achilles, E.I., Maus, V., Fink, G.R., et al., 2016. [Hemichorea with Contralateral High Signal Intensity Putaminal Lesion on T1-Weighted Images in Non-Ketotic Hyperglycemia]. *Fortschr Neurol Psychiatr*. 84(4), 222-225.
- [13] Branca, D., Gervasio, O., Le Piane, E., et al., 2005. Chorea induced by non-ketotic hyperglycaemia: a case report. *Neurol Sci*. 26(4), 275-277.
- [14] Cheema, H., Federman, D., Kam, A., 2011. Hemichorea-hemiballismus in non-ketotic hyperglycaemia. *J Clin Neurosci*. 18(2), 293-294.
- [15] Chung, S.J., Im, J.H., Lee, M.C., et al., 2004. Hemichorea after stroke: clinical-radiological correlation. *J Neurol*. 251(6), 725-729.
- [16] Ehrlich, D.J., Walker, R.H., 2017. Functional neuroimaging and chorea: a systematic review. *J Clin Mov Disord*. 4, 8.
- [17] Bhidayasiri, R., Truong, D.D., 2004. Chorea and related disorders. *Postgrad Med J*. 80(947), 527-534.
- [18] Pandey, S., Chorea, J., 2013. *Assoc Physicians India*. 61(7), 471-4, 483.