

ARTICLE

New Concept of Whiplash Injuries Rehabilitation

Piotr Godek^{1*} Michał Guzek² Jakub Przychodzeń²

1. Sutherland Medical Center, Warszawa, 04-036, Poland

2. RehaDent, Warszawa, Poland

ARTICLE INFO

Article history

Received: 7 December 2020

Accepted: 2 June 2021

Published Online: 10 June 2021

Keywords:

Whiplash injuries

Rehabilitation

Somatosensory disorder

Craniocervical injury

Pain management

ABSTRACT

Whiplash injuries are a global health problem and a significant financial burden for both health care systems, and insurance providers. The diverse symptomatology after whiplash injury both in the somatic, emotional and behavioral sphere prompted separation of the Whiplash Associated Disorders (WAD) as a separate category of diseases. The exact mechanism of whiplash injury is still under debate and theories explaining pathogenesis of WAD are very diverse ranging from purely biomechanical to neurophysiological, emphasizing central sensitization but the core disability seems to be strictly connected to somatosensory dysfunction. As a result, the optimal algorithm of rehabilitation has not been established and data published in the current literature on effectiveness of such algorithms are inconsistent. Based on the presented here of Head Neutral Reference Point (HNRP), the objective of central desensitization is to restore valid somatosensory output from Cranio - cervical Junction (CCJ). This new concept of rehabilitation after whiplash presented here is based on clinical observations and is supported by initial results.

1. Introduction

The term “whiplash” was used for the first time by Harold Crowe in 1928, during the San Francisco Orthopaedic Congress when he presented eight cases of cervical injury resulting from traffic accidents^[1].

Dynamic technological development and increase of road traffic, resulted in tremendous increase in numbers of vehicle collisions, which became a huge socio-medical problem. The most recent report of the US National Highway Traffic Safety Administration published in 2010 shows 3.9 million traffic injuries with damages to 24 million vehicles in the US in that year. The total, direct economic costs associated with these accidents were astronomical and reached \$242 billion. Together with the

indirect costs, like long-term disability, legal costs, rehabilitation costs, etc., total costs of these accidents reached a staggering \$836 billion. By comparison, the costs of direct, immediate medical treatments of all victims of car accidents, excluding fatal accidents, in 2010 were estimated at \$23.4^[2,3].

In the USA whiplash injuries account for around 83% of all traffic injuries, resulting in a total yearly incidence of between 235 - 300 / 100,000. The total cost of treating only whiplash injuries including medical care, disability, sickness absence is estimated at 3.9 billion USD annually, while including procedural and compensation costs up to 29 billion USD, due to their extent, complex symptomatology hindering treatment and a tendency to leave the long-term effects of injury are a significant socio-medical

**Corresponding Author:*

Piotr Godek,

Sutherland Medical Center, Warszawa, 04-036, Poland;

Email: piotrgodek.smc@gmail.com

problem^[4].

Due to wide variety of symptoms presented by the whiplash victims, a working group, called The Québec Task Force introduced in 1995 the term “Whiplash Associated Disorders” (WAD) to describe a set of somatic, emotional and behavioral symptoms resulting from a cervical spine injury during road collision^[1].

The onset of symptoms may be delayed up to 12-15 hours. The most common complaints are similar regardless of the time of the onset and include: neck pain, often also in the thoracic and even in the lumbar region, upper limb paraesthesia, headache, dizziness and other balance disorders, visual disturbance (double vision, accommodation disorder), auditory sensation (tinnitus), swallowing disorder, hoarseness, nausea, vomiting, and impaired concentration. Usually a physical examination reveals “only” limitation of the range of motion in the cervical segment, raised muscle tone, numerous tender points. Much less often neurological deficits are detected, and almost always nothing more than diminished cervical lordosis in radiological findings is registered.

The mechanism of the injury is much more complicated than the flexion - extension as the term “whiplash” would suggest. Many theories attempted to define the pathophysiology of the WAD, among them purely biomechanical (injury of the anterior ligament complex and facet joint compression), hydrodynamic (displacement of the cerebrospinal fluid) and neurophysiological (central sensitisation) ones, but none is regarded to adequately describe the pathophysiology of the WAD^[5,6,7].

Despite many attempts to develop an optimal algorithm for rehabilitation and in-depth analyses indicating progressive muscle disorders suggesting that activation of deep cervical muscles should be a part of the rehabilitation process, there is still lack of consensus on the optimal rehabilitation approach to whiplash injuries. This is evidenced by conclusion of the Cochrane meta-analysis prepared by Verhagen et al. regarding treatment of whiplash injuries, where it was enigmatically stated: “the trend is observed, that active therapy probably has an advantage over passive management, but none of the methods has a clear advantage over another”^[8].

Indeed, it has not been shown that any of the methods proposed thus far have definitely better outcome.

The new concept attempts to link the pathomechanics and really bothersome symptomatology of whiplash injury with the post-traumatic loss of the sense of the Head Neutral Reference Point (HNRP). The HNRP is not the same as Head Neck Center of Gravity (HNCG) described in details by Dempster (1955) as “the point located 8 mm anterior to the basion on the inferior surface of the base of

occiput or within the bone 24±5 mm from the crest of the dorsum sellae. On the surface of the head a point is located 10 mm anterior to the supratragic notch above the head of the mandible is directly lateral”^[9].

The HNRP has a much broader, functional meaning and describes position of the head which, apart from visual and vestibular control, the somatosensory system allows keeping with minimal effort. The cornerstone of this somatosensory system are mechanoreceptors, located mostly in the muscle spindles, which provide the nervous system with information about the muscle’s length and velocity of contraction, thus contributing to the individual’s ability to discern joint movement and a sense of head’s position. There is strong evidence that impairment of this system leads to a chronic neck pain, postural sway, poor position sense and dizziness^[10].

Human muscle spindles in the suboccipital area are extremely rich in mechanoreceptors, (part of Cranio-cervical Junction, CCJ) but these mechanoreceptors are also found in ligaments, joint capsules, fascia and even in dura where, besides conveying purely mechanical information, they may regulate cranial blood vessels, as it was shown in animal studies^[11,12].

It is widely accepted that mechanoreceptor impulses from the occiput to C3 have a direct impact on vestibular nuclear complex (VNC) - a reflex centre that coordinates vision and neck movements. This same mechanoreceptor input also converges on the central cervical nucleus (CCN), which is a pathway to the cerebellum integrating vestibular, ocular and proprioceptive information. Simplistically speaking, the mechanoreceptor input from the upper cervical region helps to coordinate vision, balance, movement of the neck and postural control. Disruption of normal afferent/ efferent stream after whiplash injuries produce more harm to the upper cervical region than to the lower one, because the upper region contains more muscle spindles and has more complicated connections to the visual and vestibular systems, and receives feedback from it. Malmström et al. have shown how powerful is mechanoreceptor system of the CCJ because even subjects with bilateral vestibulopathy did not differ significantly from controls in their ability to reproduce different target positions^[13].

Thus, the mechanoreceptor system of upper cervical spine can be viewed as independent Head Position Control System (HPCS). Through afferent pathways it relays to the central nervous system the least necessary afferent stimulation, and with minimal energy expenditure of well-balanced muscles the head is kept around HNRP. In clinical practice, achieving the correction of the habitual defective malposition of the head enables the patient to

breathe freely and swallow without pain and any effort.

The HNRP pattern is defined by 2 lines:

1) a vertical line passes through the center of the sternal jugular notch, the center of the chin (gnation), nasion and the center of the glabella;

2) an horizontal line passes from the nasal chondro-osseous junction to the supratragic notch.

The malalignment of these lines from the vertical reference line in the frontal plane (usually in the side-bending and rotation direction) and from the horizontal reference line in the sagittal plane (usually in the extension direction) is a measure of true HPCS dysfunction.

The loss of HNRP after whiplash injury results not only in defective stimulation from position receptors to muscles which produce abnormal head position, but can be responsible for disturbance of brain perfusion and “dark cloud” of behavioral symptoms (catastrophic attitude, kinesiphobia, dysphoric mood) which jeopardise rehabilitation results. Restoring of HNRP may be of fundamental importance for the rehabilitation process.

2. Methodology

Successful evaluation of the patient begins as usual with a detailed history-taking process. Subjects with a loss of HNRP report typical symptoms of dizziness, tinnitus, visual disturbances (diplopia, accommodation disorders), impaired vocal function due to irritation of laryngeal recurrent nerve (muscle imbalance results elevated hyoid bone and narrowed passage conflicting the nerve), dysphagia, hoarseness, nausea, impaired concentration and nonradicular pattern paraesthesia.

Inspection indicates significant malalignment of vertical and horizontal line from reference lines mentioned above. (Figure 1 & 2)



Figure 1. Frontal view with malalignment of vertical line in side bending.

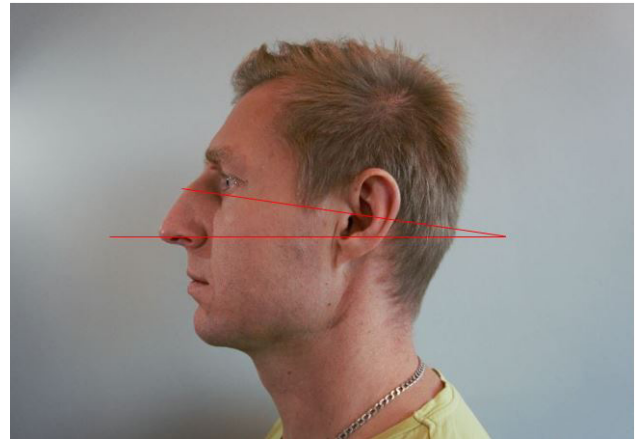


Figure 2. Lateral view with malalignment of horizontal line in extension pattern

Soft tissue palpation reveals muscle tone disbalance - raised tone of suboccipital mm. (SOM), sternocleidomastoid m. (SCM) and suprahyoid mm. (SHM) with hypoactive longus colli m. and longus capitis m. (LCoM, LCaM).

Then follows analysis of CCJ mobility and ligaments integrity.

Test for alar ligaments - during passive rotation of the head (e.g. to the left) countermovement of C2 spinous process can be felt by the thumb placed on its right aspect - if no consecutive movement of C2 spinal process during the first 15 deg. of rotation occurs it may indicate alar ligaments injury.

Sharp purser test - passive compression of C2 spinous process with a thumb with consecutive resisted short active flexion of the upper cervical spine, when “click” or loss of support under the thumb is felt the transverse ligament of C1 may be compromised.

Passive translation test for C0/C1 segment - manual assessment by the three-finger grip (mandibular angle, C1 transverse process, mastoid) - translational passive movements - C0 / C1 is normally combined with lateral flexion. If no connection between translation and side-bending - dysfunction C0/C1 is likely.

Passive rotation test for C0/C1 segment - two - finger grip (occiput, C1) - extension test with an unilateral side-bending and rotation - normally occiput can easily approximate C1.

Special consideration is given to detection of compensatory mobility malfunctions.

Open mouth test - in normal conditions two - fingers wide opening occurs without co-existent compensatory movements and no painful protrusion of the mandible is noted (physiologically up to 30 mm). (Figure 3).



Figure 3. Open mouth test with properly made correction of HNRP

Subjects after whiplash present extension in the upper cervical segment, side - bending or elevation /compression to one side during mouth opening test. During active rotation of the neck malalignment usually increases significantly. (Figure 4 & 5)

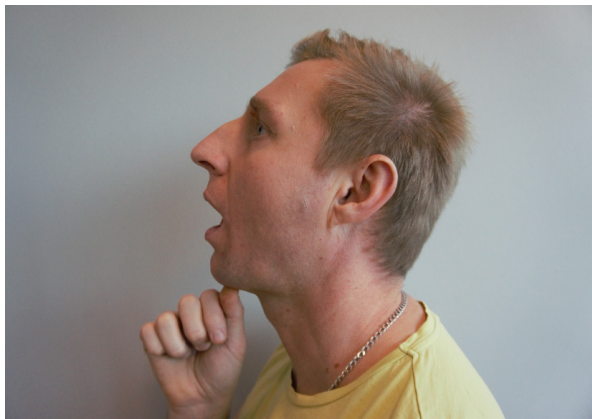

Figure 4. Open mouth test with extension pattern



Figure 5. Open mouth test with malalignment of vertical line during rotation.

Apart from significant limitations of the range of motion in the cervical segment active neck movements dis-

close wrong pattern of rotation, side - bending and flexion / extension usually with engagement of whole torso or upper limb.

Re-education of HNRP

Phase I - self-correction

Information and reassurance for the patient are crucial. It is worthy of time to start with the explanation of the treatment objective, prognosis and above all to invite the patient to be equally responsible for the final outcome as an active “co-producer”.

Mirror therapy - active self - correction of reference line following 3 points marked on the skin assisted by therapist.

Mouth opening (two - fingers wide) with active correction of horizontal lateral line assisted by therapist (repeated until no pain, resistance or compensation occurs).

Phase II - self-correction and active movement

Active rotation of the neck - the main objective is to keep corrected position of 3 reference points marked on the face and rotation is continued within comfortable range without triggering any suboccipital tension.

Phase III - self-correction, active movement, resistance

Active rotation of the neck - the main objective is to keep corrected position of 3 reference points and rotation is continued within comfortable range then followed by gentle resistance but without triggering any suboccipital tension.

Resisted mouth opening with assisted control of SCM attachments (conscious lowering of SCM hypertonus) by activation of suprahyoid muscles (repeated until no pain, resistance or compensation occurs). Recommendation for further home therapy 2-3 minutes twice a day

Resisted mouth opening with rotation and self - correction. (Figure 6).



Figure 6. Open mouth test with rotation and self-correction in vertical line

After successfully accomplishing the tasks in open chain some closed-chain tasks can be introduced e.g. active gentle pressure bregma point against wall with correction of the position of the shoulder blade in all fours supported position as an activation of LCoM and LCaM mm.

Above mentioned training sessions (ca. 45 min each) are applied usually twice a week in acute or subacute phase of WAD, then the appointments are spread to once weekly, twice monthly, once monthly until resuming full function. During each session manual intervention (mobilisation, manipulation, soft tissue release) is performed when needed.

An objective test to validate the progress of HNRP re-education is very simple - eyes closed, active head rotation and return to zero position evaluated by therapist, repetition five times both sides before beginning each new session. Patient gathers 1 point for single restoration of the target position correctly. Obtaining 10 points ends the therapy.

3. Material and Method

In the period between 01/2018 and 09/2020 totally 112 patients were qualified to rehabilitation program and were treated according to the rules described above, in the clinic Arenamed, Warsaw, Poland.

Serious neurological deficits, fractures/dislocations or operative treatment were the only excluding criteria. Two experienced physiotherapist and manual therapists took care of the patients, which were enrolled to the therapy in order of submissions. The patients were treated twice a week (8 sessions) and the follow up visit was made after two months. Most of them continued further therapy and the mean period of therapy reached 19,25 weeks (13,12 sessions) but the longest period of therapy reached even 68 weeks to resume full function.

End points: the beginning of therapy (Visit 0, V0), after 2 months of therapy (Visit 1, V1).

Outcome measure: Numeric Rating Scale (NRS, 0-10) and Neck Disability Index (NDI, 0-50).

Rehabilitation process was performed by two therapists, but the patient assigned to a given therapist was treated by him from the beginning to the end of the study.

Mean values change of NRS, NDI were compared between V0 and V1 endpoints. Percentages of patients achieving clinical response in NRS and NDI were determined according to the Minimal Important Difference (MID) with cut-off points 3/10 for NRS and 10/50 for NDI.

All calculations and graphs were performed in IBM SPSS Statistics.

4. Results

Presented analysis covers retrospective material for single-center, open study. All the patients accomplished 8 sessions of therapy and all of them were checked-up after finishing of therapy (2 months from V0). There were no serious complications during therapy, some post-procedure soreness after manual therapy occurred and lasted several hours but were generally well tolerated.

The demographic data are presented in Table 1.

Table 1. Demographic data

Total number of patients, n	112
Female, n (%)	79 (70,5)
Age, years, mean ± SD (range)	46,17±11,4 (21-74)
Duration of complaints, weeks, range	3-600
Duration of complaints, weeks, mean ± SD (range)	89,24±113,92 (3-600)
WAD phase, n (%):	
Acute phase patients,	30 (26,8)
Subacute phase patients	40 (35,7)
Chronic phase patients	42 (37,5)

Mean NRS at the beginning of therapy was 3,61 (SD=1,55) and after accomplishing therapy 2,14 (SD=1,08). (Figure 7)

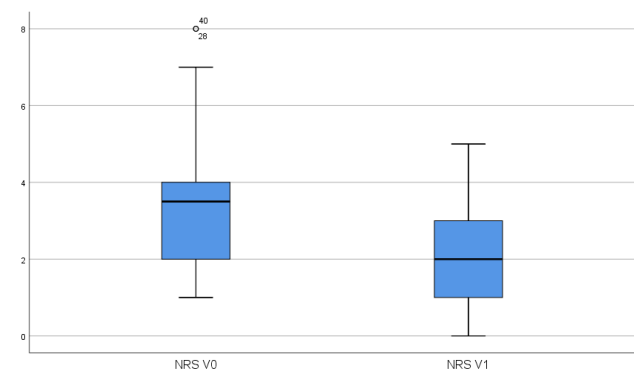


Figure 7. Mean NRS values before and after therapy.

Mean NDI at the beginning of therapy was 21,25 (SD=8,28) and after accomplishing therapy 12,31 (SD=5,93). (Figure 8)

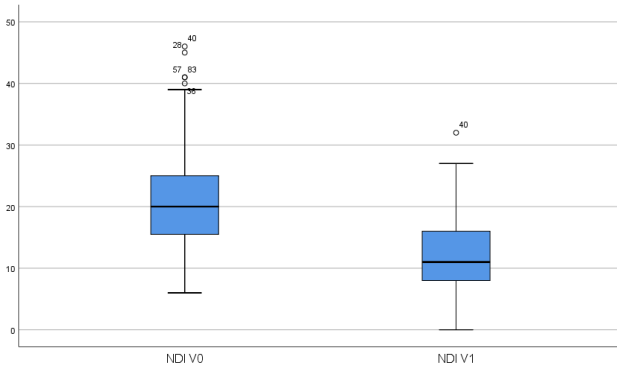


Figure 8. Mean NDI values before and after therapy

Mean NRS and NDI values evolution depending on the phase of complaints are presented in Figure 9 and 10.

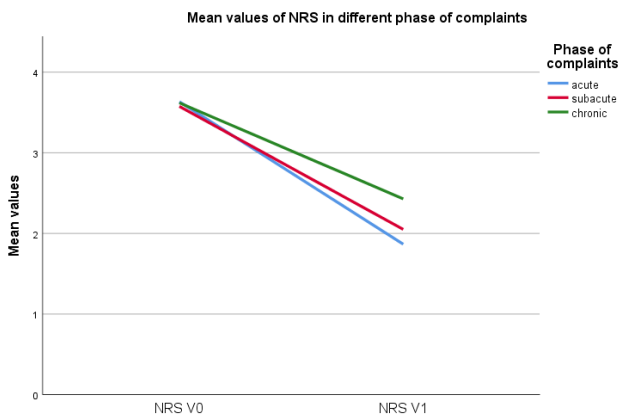


Figure 9. NRS mean values evolution depending on the phase of complaints.

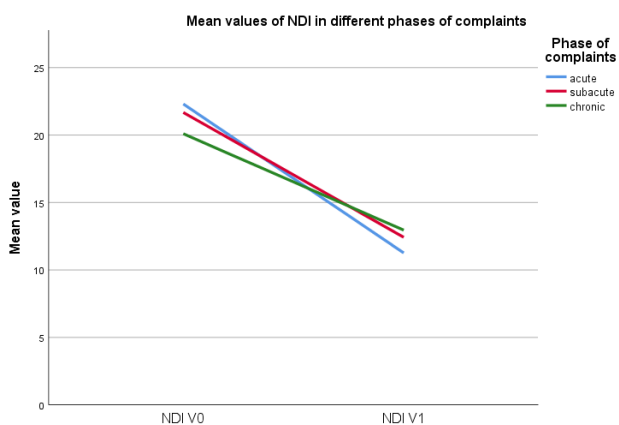

Figure 10. NDI mean values evolution depending on the phase of complaints..

Only 21,4% of patients achieved MID (at least 3 points difference) for NRS, but MID (at least 10 points difference) in NDI achieved 41,9% of patients.

5. Discussion

The population treated was mostly female, middle aged but very inhomogeneous considering duration of complaints (3-600 weeks). Both mean values of NRS and NDI were reduced after treatment with much better dynamics in acute and subacute than chronic cases. Nevertheless no improvement in NRS was noted by 29 patients (25,8%) albeit real worsening of outcomes was found only in 2 cases (1,8%). Three of cases reported worsening of outcomes in NDI (2,7%). Many more patients achieved MID in NDI (41,9%) than in NRS (21,4%). It may suggest that patients are doing better functionally after therapy but the encoded pain especially in the chronic cases need some more time to resolve and to be really noticed by patient.

Presented data should be treated as preliminary and with caution because there is no information about additional e.g. pharmacological or psychological consecutive care. There is also a lack of information and comparison study about various initial treatments which were implemented before admission for rehabilitation process.

Considering outcomes and prognosis of WAD the Québec Task Force (1995), assumed that whiplash injuries have mostly good prognosis, because 87% of patients after 6 months and 97% after 12 months declare the end of the period of insurance benefits due to incapacity for work [1]. Completely different data are provided by Barnsley et al. (1994), where 14 to 42% of patients develop chronic complaints (lasting over 6 months), and 10% remain with chronic, persistent pain [14].

In more recent studies, the percentage of chronic pain developed after whiplash trauma varies widely between 2 and 58%, but the most common range is 20-40% [15,16].

It means that there is much to discover in the area of optimal rehabilitation care after whiplash injuries. Nevertheless, some facts seem to support the theory of HNRP restoration as an effective tool of WAD care.

One of the most popular theories considering whiplash pathomechanics emphasizes eccentric contraction of the neck muscles during inertial movement and assumes a rapid defensive contraction of muscles causing their micro damages and overcorrection of muscle spindles with a looped increased muscle tone [17].

Persistent excessive muscle tension in a patient's specific pattern may lead to malalignment of HNRP.

We know for sure that immobilization in the orthopaedic collar, beyond absolute necessity, delays recovery and does not reduce pain, and may also strengthen kinesiophobia [18].

Regardless of the dominant mechanism of trauma, the eventful and possibly chronic course of WAD is indeed a

dysfunctional processing of the pain signal at the level of the spinal cord and upper cerebral centres with peripheral and central sensitization. It was confirmed by numerous experiments showing changes in cerebral regional blood distribution in functional MRI, increased sensitivity to both mechanical and thermal stimuli of patients with WAD similar to those encountered, among others in fibromyalgia and algodystrophy^[19,20,21,22].

Unproper balanced CCJ can profoundly change perfusion of the brain when the theory of mechanoreceptors impact on intracranial vascular tonus is still potent. Neglecting of HNRP may be the causative that the results of WAD treatment donated by many authors regardless of the method, are still unsatisfactory for both the acute and chronic phase. Especially in cases of moderate to severe initial symptoms, many patients in these groups experience central pain sensitization and its chronification. Rehabilitation and manual therapy only slightly modify the symptoms in these patients (reduction by 2 points per 10 in NRS which is very similar to our data - 1,47), so efforts are aimed at broadening the spectrum of specialists involved in the care of a patient with WAD by psychologists, psychiatrists, specialists in pain management, occupational therapists, etc.

It has been shown that cerebral hypoperfusion in the parietal-occipital border zone can be responsible for visual disturbances (blurring the contours of objects, accommodation disorders) and certain behavioral disorders in the form of difficulties in the formulation of thoughts, distraction or, on the contrary, the inability to divert attention from one imposed thought, which patients with chronic WAD often complain about^[23,24].

Patients with WAD present extensive zones of increased pain sensitivity, covering areas of the body that could in no way have had any injury as a result. It also causes specific characterological changes in these patients very often with an increased level of anxiety, catastrophising, kinesiophobia, withdrawal or sometimes aggression and claim attitude, which makes cooperation with a physician or a physiotherapist very difficult. Kinesiophobia in the chronic phase may be responsible for paravertebral muscle atrophy and fat infiltration observed in MRI - especially in the deep layer.^[25,26,27,28]

We know that as a result of whiplash injury, tensions between the superficial and deep muscles of the neck are disorganized. The predominance of SCM tension (confirmed by EMG) and inhibition of the LCoM function causes a change in the curvature of the cervical segment, significant limitation of the range of motion and protraction of the head, which promotes shortening of the middle layer (scalene muscles) and inhibits even more multifidus

and LCoM. This, of course, also affects the incorrect timing of neck muscles cooperating with shoulder girdle movements, which means that with repetitive movements of the upper limbs, the pain is intensified^[29,30].

On this basis, the concept of “waking up” of the LCoM with the simultaneous relaxation of the SCM was created by specific, precise exercises that selectively activate deep layer muscles without simultaneously involving superficial muscles.

Another supporting HNRP restoration paradigm can be study of Bunketorp et al. who proved that tailor-made therapy, individualized and supervised by a physiotherapist, is a more effective method of muscle re-education after whiplash injuries than instructing home exercises alone, no matter how precise they are^[31].

There are even reports that the improvement between muscle balance between LCoM and SCM through precise flexion exercises at the CCJ transition zone lead to a reversal of the fat infiltration process^[32,33].

Further intensive research is needed to develop a coherent and scientifically proven optimal strategy for the treatment of acute whiplash injuries, preventing the transition to a chronic form.

6. Conclusions

- 1) The concept of the HNRP is strongly related to the sensorimotor control of the CCJ.
- 2) Recovery of the HNRP may facilitate the reprogramming of the dysfunctional sensorimotor control of the CCJ after whiplash injuries and seems to be useful in the process of central desensitisation and individualized rehabilitation.
- 3) Based on the preliminary clinical experience, the method of HNRP recovering seems to be effective, however, it requires confirmation on a larger number of participants in a study with a control group and a sufficiently long observation period.

References

- [1] Spitzer W. O., Skvtn M. L., Salmi L. R., et al. Scientific monograph of the Quebec task force on whiplash-associated disorders: redefining “whiplash” and its management. *Spine*. 1995; 20:2-235. DOI: 10.1097/00007632-199805010-00015.
- [2] Blincoe L, Miller T, Zaloshnja E, Lawrence B. The Economic and Societal Impact of Motor Vehicle Crashes, 2010. (Revised) (Report No. DOT HS 812 013). Washington, DC: National Highway Traffic Safety Administration; 2015.
- [3] Yadla S, Ratliff JK, Harrop JS. Whiplash: diagnosis,

- treatment, and associated injuries. *Curr Rev Musculoskelet Med.* 2008 Mar;1(1):65-8.
DOI: 10.1007/s12178-007-9008-x. PMID: 19468901; PMCID: PMC2684148.
- [4] van der Velde G, Yu H, Paulden M, Côté P, Varatharajan S, Shearer HM, Wong JJ, Randhawa K, Southerst D, Mior S, Sutton D, Jacobs C, Taylor-Vaisey A. Which interventions are cost-effective for the management of whiplash-associated and neck pain-associated disorders? A systematic review of the health economic literature by the Ontario Protocol for Traffic Injury Management (OPTIMa) Collaboration. *Spine J.* 2016 Dec;16(12):1582-1597.
DOI: 10.1016/j.spinee.2015.08.025. Epub 2015 Nov 26. PMID: 26631759.
- [5] Stemper BD, Yoganandan N, Pintar FA, Maiman DJ. Mechanism of injury. In: Sterling M, Kenardy J editors. *Whiplash evidence base for clinical practice.* Elsevier, 2011, pp. 16-28.
- [6] Tisherman R et al. Biomechanical contribution of the alar ligaments to upper cervical stability. *J Biomech.* 2019 (11) 23:109508.
- [7] Bogduk N. On cervical zygapophysial joint pain after whiplash. *Spine (Phila Pa 1976).* 2011 Dec 1;36(25 Suppl): S194-9. Barnsley L, Lord S, Bogduk N. Whiplash injury: clinical review. *Pain* 58(3) 1994:283-307.
- [8] Verhagen AP, Scholten-Peeters GG, van Wijngaarden S, de Bie RA, Bierma-Zeinstra SM. Conservative treatments for whiplash. *Cochrane Database Syst Rev.* 2007 Apr 18;(2):CD003338.
DOI: 10.1002/14651858.CD003338.pub3. PMID: 17443525.
- [9] Yoganandan N, Pintar FA, Zhang J, Baisden JL. Physical properties of the human head: mass, center of gravity and moment of inertia. *J Biomech.* 2009 Jun 19;42(9):1177-92.
DOI: 10.1016/j.jbiomech.2009.03.029. Epub 2009 May 9. PMID: 19428013.
- [10] Stanton TR, Leake HB, Chalmers KJ, Moseley GL. Evidence of Impaired Proprioception in Chronic, Idiopathic Neck Pain: Systematic Review and Meta-Analysis. *Phys Ther.* 2016 Jun;96(6):876-87.
DOI: 10.2522/ptj.20150241. Epub 2015 Oct 15. PMID: 26472296; PMCID: PMC4897597.
- [11] Kristjansson E, Treleaven J. Sensorimotor function and dizziness in neck pain: implications for assessment and management. *J Orthop Sports Phys Ther.* 2009 May;39(5):364-77.
DOI: 10.2519/jospt.2009.2834. PMID: 19411769.
- [12] Nakamura M, Jang IS. Characterization of dural afferent neurons innervating cranial blood vessels with the dura in rats. *Brain Res.* 2018 Oct 1;1696:91-102.
DOI: 10.1016/j.brainres.2018.06.007. Epub 2018 Jun 15. PMID: 29886250.
- [13] Malmström EM, Karlberg M, Fransson PA, Lindbladh J, Magnusson M. Cervical proprioception is sufficient for head orientation after bilateral vestibular loss. *Eur J Appl Physiol.* 2009 Sep;107(1):73-81.
DOI: 10.1007/s00421-009-1097-3. Epub 2009 Jun 9. PMID: 19506897.
- [14] Barnsley L, Lord S, Bogduk N. Whiplash injury. *Pain.* 1994 Sep;58(3):283-307.
DOI: 10.1016/0304-3959(94)90123-6. PMID: 7838578.
- [15] Côté P, Cassidy JD, Carroll L, Frank JW, Bombardier C. A systematic review of the prognosis of acute whiplash and a new conceptual framework to synthesize the literature. *Spine (Phila Pa 1976).* 2001(10)1;26(19): E445-58.
- [16] Scholten-Peeters GG et.al. Prognostic factors of whiplash-associated disorders: a systematic review of prospective cohort studies. *Pain.* 2003 (7);104(1-2):303-22.
- [17] Yoganandan N, Brian D, Stemper BD, Rao RD. Patient Mechanisms of Injury in Whiplash-Associated Disorders, *Seminars in Spine Surgery* Volume 25, Issue 1, (3) 2013, pp. 67-74.
- [18] Ricciardi L, Stifano V, D'Arrigo S, Polli FM, Olivi A, Sturiale CL. The role of non-rigid cervical collar in pain relief and functional restoration after whiplash injury: a systematic review and a pooled analysis of randomized controlled trials. *Eur Spine J.* 2019 Aug;28(8):1821-1828.
DOI: 10.1007/s00586-019-06035-9. Epub 2019 Jun 18. PMID: 31214856.
- [19] Vázquez García D, Doorduyn J, Willemsen AT, Dierckx RA, Otte A. Altered Regional Cerebral Blood Flow in Chronic Whiplash Associated Disorders. *EBioMedicine.* 2016 Aug; 10:249-57.
DOI: 10.1016/j.ebiom.2016.07.008. Epub 2016 Jul 14. PMID: 27444853; PMCID: PMC5006659.
- [20] Freitag P, Greenlee MW, Wachter K, Ettlin TM, Radue EW. fMRI response during visual motion stimulation in patients with late whiplash syndrome. *Neurorehabil Neural Repair.* 2001;15(1):31-7.
DOI: 10.1177/154596830101500105. PMID: 11527277.
- [21] Häggman-Henrikson B, Lampa E, Nordh E. Altered thermal sensitivity in facial skin in chronic whiplash-associated disorders. *Int J Oral Sci.* 2013 Sep;5(3):150-4.
DOI: 10.1038/ijos.2013.42. Epub 2013 Jul 19.

- PMID: 23867844; PMCID: PMC3967328.
- [22] Myrtveit SM, Skogen JC, Sivertsen B, Steingrimsdóttir ÓA, Stubhaug A, Nielsen CS. Pain and pain tolerance in whiplash-associated disorders: A population-based study. *Eur J Pain*. 2016 Jul;20(6):949-58. DOI: 10.1002/ejp.819. Epub 2015 Nov 16. PMID: 26568528; PMCID: PMC5063105.
- [23] Biendara J, Otte A. Whiplash Syndrome- a disorder of the brain? *Hell J Nucl Med*. 2017 May-Aug;20(2):110-112. DOI: 10.1967/s002449910550. Epub 2017 Jul 12. PMID: 28697186.
- [24] Otte A. Pathophysiological interrelated deactivation/activation processes in the exhausted brain after whiplash injury. *Hell J Nucl Med*. 2019 May-Aug;22(2):92-95. DOI: 10.1967/s002449911000. Epub 2019 Jul 7. PMID: 31273349.
- [25] Elliott JM, O'Leary S, Sterling M, Hendrikz J, Pedler A, Jull G. Magnetic resonance imaging findings of fatty infiltrate in the cervical flexors in chronic whiplash. *Spine (Phila Pa 1976)*. 2010 Apr 20;35(9):948-54. DOI: 10.1097/BRS.0b013e3181bb0e55. PMID: 20118837.
- [26] Elliott J, Pedler A, Kenardy J, Galloway G, Jull G, Sterling M. The temporal development of fatty infiltrates in the neck muscles following whiplash injury: an association with pain and posttraumatic stress. *PLoS One*. 2011;6(6): e21194. DOI: 10.1371/journal.pone.0021194. Epub 2011 Jun 16. PMID: 21698170; PMCID: PMC3116885.
- [27] Elliott JM, Courtney DM, Rademaker A, Pinto D, Sterling MM, Parrish TB. The Rapid and Progressive Degeneration of the Cervical Multifidus in Whiplash: An MRI Study of Fatty Infiltration. *Spine (Phila Pa 1976)*. 2015 Jun 15;40(12): E694-700. DOI: 10.1097/BRS.0000000000000891. PMID: 25785961; PMCID: PMC4466088.
- [28] Pedler A, McMahon K, Galloway G, Durbridge G, Sterling M. Intramuscular fat is present in cervical multifidus but not soleus in patients with chronic whiplash associated disorders. *PLoS One*. 2018 May 24;13(5): e0197438. DOI: 10.1371/journal.pone.0197438. PMID: 29795590; PMCID: PMC5967697.
- [29] Jull G, Kristjansson E, Dall'Alba P. Impairment in the cervical flexors: a comparison of whiplash and insidious onset neck pain patients. *Man Ther*. 2004 May;9(2):89-94. DOI: 10.1016/S1356-689X(03)00086-9. PMID: 15040968.
- [30] Falla DL, Jull GA, Hodges PW. Patients with neck pain demonstrate reduced electromyographic activity of the deep cervical flexor muscles during performance of the craniocervical flexion test. *Spine (Phila Pa 1976)*. 2004 Oct 1;29(19):2108-14. DOI: 10.1097/01.brs.0000141170.89317.0e. PMID: 15454700.
- [31] Bunketorp L, Lindh M, Carlsson J, Stener-Victorin E. The effectiveness of a supervised physical training model tailored to the individual needs of patients with whiplash-associated disorders--a randomized controlled trial. *Clin Rehabil*. 2006 Mar;20(3):201-17. DOI: 10.1191/0269215506cr934oa. PMID: 16634339.
- [32] O'leary S, Jull G, Van Wyk L, Pedler A, Elliott J. Morphological changes in the cervical muscles of women with chronic whiplash can be modified with exercise-A pilot study. *Muscle Nerve*. 2015 Nov;52(5):772-9. DOI: 10.1002/mus.24612. Epub 2015 Sep 3. PMID: 25702919; PMCID: PMC4545448.
- [33] Jull GA, Falla D, Vicenzino B, Hodges PW. The effect of therapeutic exercise on activation of the deep cervical flexor muscles in people with chronic neck pain. *Man Ther*. 2009 Dec;14(6):696-701. DOI: 10.1016/j.math.2009.05.004. Epub 2009 Jul 25. PMID: 19632880.