

REVIEW

Unusual Metastases to Diaphragm and Spleen from Adenocarcinoma of Lung Detected by ¹⁸F-FDG PET/CT Imaging: A Case Report

Anindita Rani Paul^{1*} Rajib Paul Chowdhury² Pritam Saha Podder³ Umme Saoda¹

1. Institute of Nuclear medical Physics, AERE, Savar, Dhaka-1349, Bangladesh

2. Upazila health Complex, Bhuapur, Tangail-1960, Bangladesh

3. Department of Pharmacy, Jahangirnagar University, Savar-1342, Dhaka, Bangladesh

ARTICLE INFO

Article history

Received: 23 December 2019

Accepted: 14 January 2020

Published Online: 31 March 2020

Keywords:

PET/CT

Lung carcinoma

Diaphragm metastasis

Splenic metastasis

ABSTRACT

Globally, carcinoma of lung is the predominant cause of cancer death among both men and women. While hematogenous spread from primary lung cancer to multiple other organs is frequently reported, metastases of malignant tumors to diaphragm and spleen are rare. Nowadays, Positron emission tomography (PET) with ¹⁸F- fluorodeoxyglucose (FDG) has emerged in such a way that it has become an effective imaging technology for the evaluation of different carcinomas, particularly for cancer staging and follow up after therapy. PET scan is able to provide metabolic information. In this case, we present an attractive unified PET/CT scan image in a patient with lung carcinoma having unusual diaphragm and splenic metastases. So, PET/CT imaging could strongly identified rare and unusual metastatic sites of cancer and added more appropriate staging in patient with carcinoma of lung.

1. Introduction

Globally, carcinoma of lung is the predominant cause of cancer death among both men and women^[1]. While there has been advancements in imaging modalities in the last twenty years, the maximum carcinoma of lung are still only identified due to evolution of remote metastases. The spread of blood-borne metastases to numerous organs is usually identified and documented. The most common metastatic sites from carcinoma of lung are liver, adrenal glands, bone and brain^[1]. Metastases of malignant tumors to spleen and diaphragm are rare^[2,3]. Nowadays, Positron emission tomography (PET) with ¹⁸F- fluorodeoxyglucose (FDG) has emerged in such a way that it has become an effective imaging

technology for the evaluation of different carcinomas, particularly for cancer staging and follow up after therapy. PET scan is able to provide metabolic information^[2]. In this case report, we introduce an attractive unified PET/CT scan image in a patient with lung carcinoma having unusual diaphragm and splenic metastases.

2. Case Report

This 50 years-old patient was referred to Institute of Nuclear medical Physics, Savar for initial staging of adenocarcinoma in left lung (upper Zone). PET/CT scan image was taken 45 min after 5 mCi FDG injection (Figure 1). Maximum Intensity Projection (MIP) image of PET/CT (a), Coronal view of PET/CT fusion image (b) and cross

*Corresponding Author:

Anindita Rani Paul,

Institute of Nuclear medical Physics, AERE, Savar, Dhaka-1349, Bangladesh;

Email: aninditapaul981@gmail.com

sectional image at thoracic level (c) demonstrated a 87 × 44 mm left upper lobe mass with intense hypermetabolism (SUVmax 12.8). PET/CT image (d) and corresponding CT image (e) showed thickening (8.5 mm) of left crus of the diaphragm with SUVmax 13.5. Additionally, a 18 mm subcapsular hypodense lesion on spleen with moderate hypermetabolism were detected (SUVmax 6.7) (e, f). PET/CT imaging can identify definite metastatic lesions into the diaphragm and spleen (d, f).

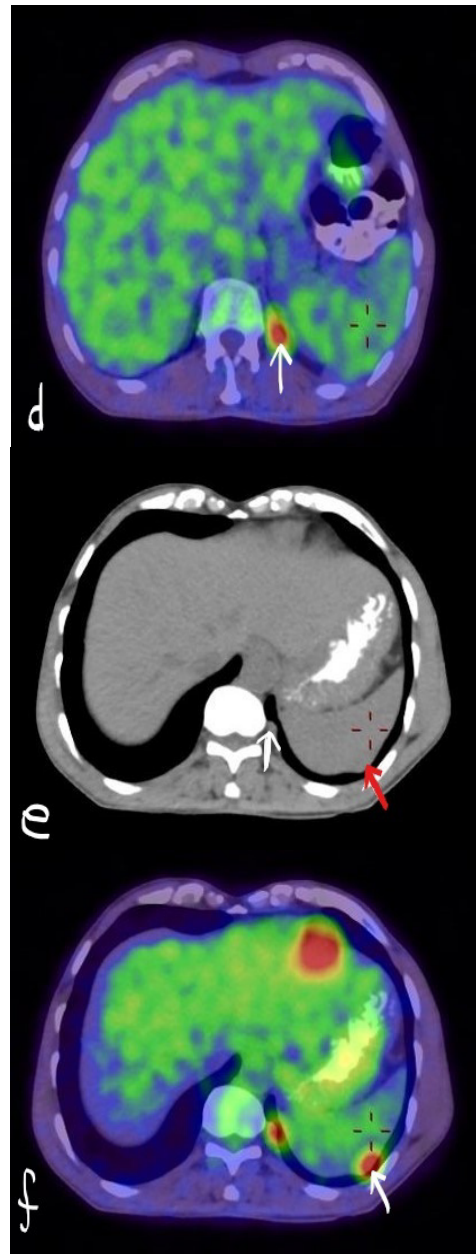
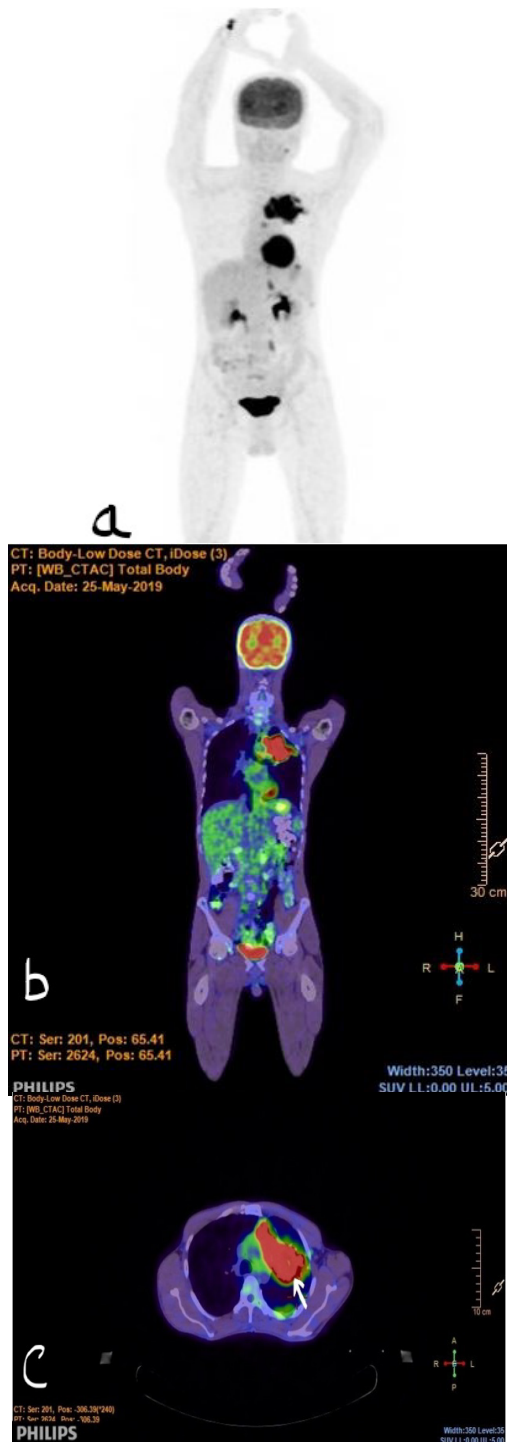


Figure 1. Positron Emission Tomography (PET-CT) scan image of this Case patient

Note: MIP view of PET-CT scan (a) Coronal view of PET-CT hybrid image (b) and cross sectional view at thoracic level (c) demonstrated a 87 × 44 mm mass with intense hypermetabolism (SUVmax 12.8) in left lung upper lobe. PET-CT image (d, White arrow) and corresponding CT image (e, White arrow) showed thickening (8.5 mm) of left crus of the diaphragm with SUVmax 13.5. Additionally, a 18 mm subcapsular hypodense lesion on spleen with moderate hypermetabolism were detected (SUVmax 6.7) in PET-CT image (f, white arrow) and corresponding CT image (e, red arrow).

3. Discussion

Neither diaphragm nor splenic invasion was verified histologically on a stage IV lung carcinoma patient having distant metastases. This is because an invasive biopsy

would be required. The pattern of FDG uptake in benign pathologic conditions, as well as physiological variants and metastatic disease is clearly different without any histopathological diagnosis. Recognising hypermetabolic foci at diaphragm in patients having pulmonary pathology is quite significant. Bilateral high FDG uptake at the crura of diaphragm is usually due to hyperventilation but in this case FDG uptake occurs unilaterally^[4]. Asymmetrical hypermetabolic focus which is not on the expected physiological area in the upper abdomen is difficult to diagnosis on PET/CT image^[5]. Furthermore, PET/CT fusion imaging has ability to detect the benign nature of focal normal fatty tissue uptake.

Carcinoma of lung can be classified histopathologically into small cell lung carcinoma (SCLC-15% to 20%) and non-small cell lung carcinoma (NSCLC-80%). Adenocarcinoma (50% of cases), squamous cell carcinoma (40% of cases), large-cell carcinoma (almost 10% of cases), and rarely adenosquamous carcinoma are histological subtypes of NSCLC. PET/CT is an accepted modern imaging technology for both mediastinal and distant staging of NSCLC. Presence of widespread metastatic involvement identifies and categorizes the patient as having stage IV disease. The usual metastatic sites from NSCLC are liver, adrenal glands, bone and brain^[6]. Rarely, it has been reported that NSCLC metastases are present in soft tissue, kidney, peritoneum, spleen, pancreas, intestine, bone marrow, eye, ovary, thyroid, heart, breast, nasal cavity, and tonsils^[7]. Unusual diaphragm and splenic metastases from lung carcinoma were depicted in this case report. Invasion of malignant tumors to spleen and to diaphragm are rarely observed^[2,3]. Currently the documented incidence of splenic metastasis from primary lung cancer is 1.2–5.6%. Metastasis to spleen is predominantly noted in the extreme stage as part of a widespread metastatic disease. Generally at this stage 3–6 other organs are also involved as well^[3].

4. Conclusion

Although the patient in this case was already at stage IV,

PET/CT could strongly identified rare and unusual metastatic sites of cancer and added more appropriate staging. PET/CT fusion image was able to find out lesions to a greater extent than where either PET or CT was used alone. Whatmore, PET-CT imaging provides excellent anatomic information of pathological FDG uptake.

References

- [1] Molina JR, Yang P, Cassivi SD, Schild SE, Adjei AA: Non-small cell lung cancer: epidemiology, risk factors, treatment, and survivorship. *Mayo Clin Proc.* 2008, 83: 584-594.
- [2] Kara PO, Gedik GK, Sarı O, and Özbek O Rare Thyroid Cartilage and Diaphragm Metastases from Lung Cancer Visualized on F-18 FDG-PET/CT Imaging. *Mol Imaging Radionucl Ther.* 2011 Aug; 20(2): 70–72. DOI: 10.4274/MIRT.019882
- [3] Mitsimponas N, Mitsogianni M, Crespo F, Hartmann k-A, Diederich S, Klosterhalfen B et al. Isolated Splenic Metastasis from Non-Small-Cell Lung Cancer: A Case Report and Review of the Literature. *Case Rep Oncol.* 2017;10(2): 638–643. DOI: 10.1159/000478002
- [4] Cook GJ, Fogelman I, Maisey MN. Normal physiological and benign pathological variants of 18-fluoro-2-deoxyglucose positron-emission tomography scanning: potential for error in interpretation. *Semin Nucl Med.* 1996, 26(4): 308–314.
- [5] Bar-Shalom R, Gaitini D, Keidar Z, Israel O. Non-malignant FDG uptake in infradiaphragmatic adipose tissue: a new site of physiological tracer biodistribution characterised by PET/CT. *Eur J Nucl Med Mol Imaging.* 2004, 31(8): 1105–1113.
- [6] Reck M, Gatzemeier U. Chemotherapy in stage-IV NSCLC. *Lung Cancer.* 2004, 45(Suppl 2): 217–222.
- [7] Niu FY, et al. Distribution and prognosis of uncommon metastases from non-small cell lung cancer. *BMC Cancer.* 2016, 16: 149. DOI: 10.1186/s12885-016-2169-5